AIXPLORER MultiWave

White Paper

SUPERSONIC imagine

The Theragnostic Company™

ShearWave™ Elastography Accurately Assesses Liver Fibrosis in Patients with Chronic Hepatitis B

Vivian YF Leung, PhD, Winnie CW Chu, MD*
Department of Imaging & Interventional Radiology, The Chinese University of Hong Kong, Prince of Wales Hospital, Hong Kong

* *Contact: winnie@med.cuhk.edu.hk*

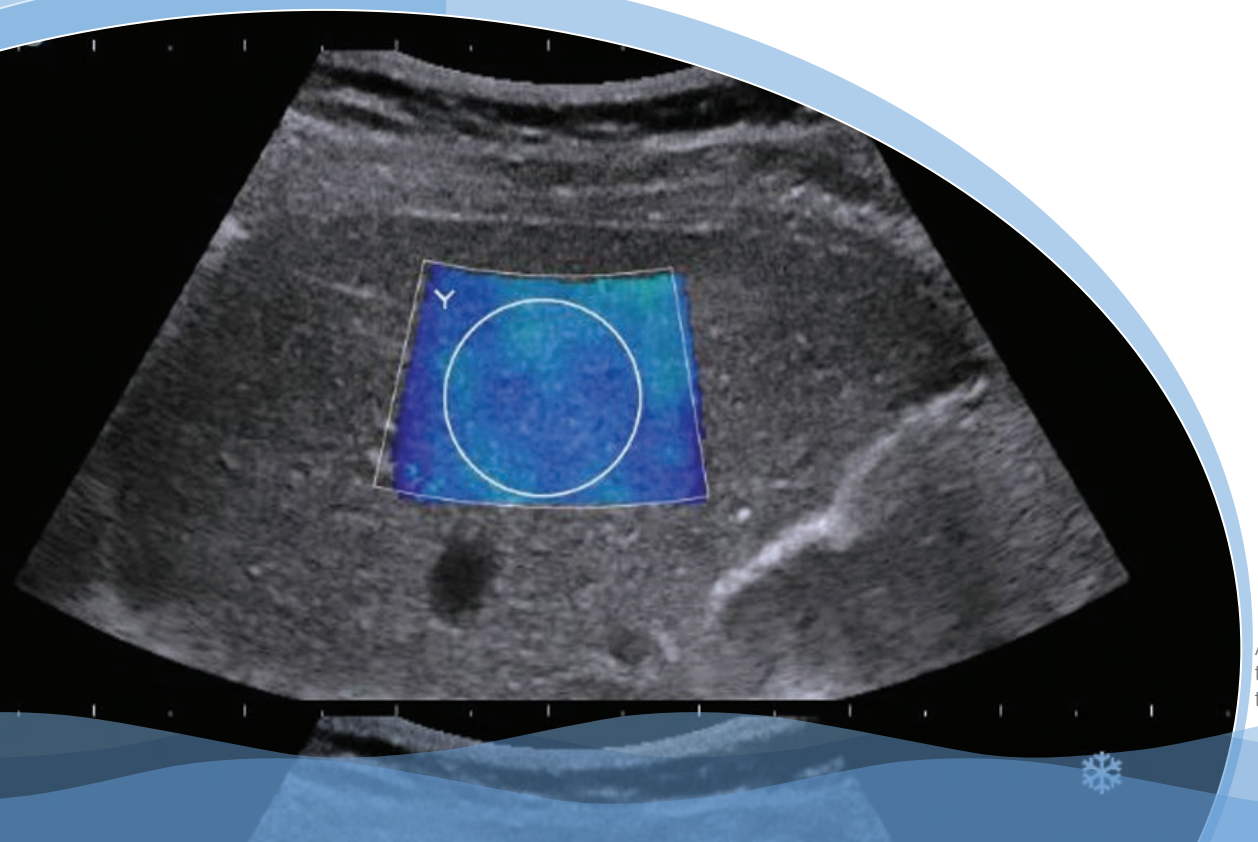

Aixplorer's quantification tool is available outside the USA

Introduction

Ultrasound (US) imaging plays a major role in the global management of patients with chronic liver diseases. Thanks to its wide spectrum of clinical applications, ultrasound collects valuable information for diagnostic purposes, patient follow-up, and therapeutic decision-making[1]. Its use covers:

- Analysis of liver parenchyma echotexture to assess the risk or the severity of chronic liver disease (such as changes in size of liver segments or liver dysmorphia and signs of portal hypertension),
- Detection and characterization of nodules in the context of cirrhosis, especially in order to manage hepatocellular carcinomas (HCC) as early as possible,
- Guidance and monitoring of percutaneous focal minimally invasive treatments (radiofrequency ablation, cryogeny, etc…,) of lesions such as HCC
- Evaluation of the patient's therapeutic response.

While conventional US imaging is very useful for global assessment of the liver, it has limitations in the assessment of diffuse liver diseases. Due to its subjective nature and variability in assessing alterations of the hepatic parenchyma echotexture and liver dysmorphia, conventional US imaging is not able to differentiate hepatic fibrosis stages accurately. Elasticity imaging and especially ShearWave™ Elastography (SWE™) may address this current limitation to help detect and stage liver fibrosis[2]. The benefits of SWE in the management of patients with chronic liver disease due to Hepatitis C infection have already been demonstrated[3-5]. The reliability and applicability of the technique have been evaluated as well and were reported to be similar to already existing non-invasive techniques[5-6].

The quantification of hepatic fibrosis is of critical importance in the management of patients with chronic Hepatitis B infection, as it impacts the treatment indication. Patients recommended for antiviral therapy should have these 3 factors: (1) Hepatitis B virus (HBV) DNA levels above 2,000 IU/ml, (2) serum alanine aminotransferase (ALT) levels above the upper limit of normal (ULN) and (3) moderate to severe necroinflammation of the liver as assessed by liver biopsy or non-invasive liver fibrosis assessment methods, and/or at least moderate fibrosis (METAVIR score F≥2)[7]. For patients with obvious chronic Hepatitis B (HBV DNA≥20,000 IU/ml and ALT≥2 times ULN), antiviral treatment should be started without liver fibrosis assessment, but non-invasive methods may be useful to estimate the extent of fibrosis and to rule out cirrhosis. Additionally, patients with cirrhosis and detectable HBV DNA should be treated regardless of ALT levels. The detection of cirrhosis also indicates specific monitoring for portal hypertension and its related complications, as well as for detecting developing HCC[8].

Additionally, SWE could benefit patients requiring follow-up assessment, such as (1) those under 30 years of age with normal ALT levels but high HBV DNA levels, (2) inactive chronic HBV carriers, (3) those who are monitored for cirrhotic disease progression, and (4) those followed-up for anti-fibrotic treatments.

Our experience

We have used SWE™ to study liver and spleen stiffness in a large group of normal subjects and chronic Hepatitis B carriers with biopsy correlation. The full results will be published soon (Leung VYF et al. Radiology 2013, in press). In this study we demonstrated that SWE had better correlation to liver fibrosis than another commonly used non-invasive tool, similar to results found in the context of Hepatitis C infection[3-5], especially in the assessment of early fibrotic stage METAVIR F2. Using SWE, we also showed that splenic stiffness could be linked to the severity of liver fibrosis. The optimal cutoffs in kilopascals (kPa) of liver stiffness and spleen stiffness for the identification of liver fibrosis stages have been calculated. We have concluded that SWE has been an accurate non-invasive method for assessing liver fibrosis.

Liver stiffness measurements

Our experience on 226 patients demonstrates that SWE can be used to accurately measure the stiffness of the liver in a non-invasive manner (see Figure 1). If confirmed by large prospective studies focused on HBV-infected patients, SWE may be useful to improve the indication for biopsy. This could be especially important in cirrhotic patients. In our study, we found that 10 kPa (1.8 m/s) was the optimal cut-off point for detecting cirrhosis (METAVIR F4). We also determined that 7.9 kPa (1.6 m/s) was the optimal cut-off value to detect severe fibrosis (METAVIR F3), and 7.1 kPa (1.5 m/s) was the optimal cut-off point to assess significant moderate fibrosis (METAVIR F2). In the latter cases, the demonstrated accuracy of SWE measurements would be very important to indicate anti-fibrotic treatment, whereas conventional gray scale ultrasound alone is insensitive to significant or advanced fibrosis. The clinical case presented in Figure 2 is an example of this situation.

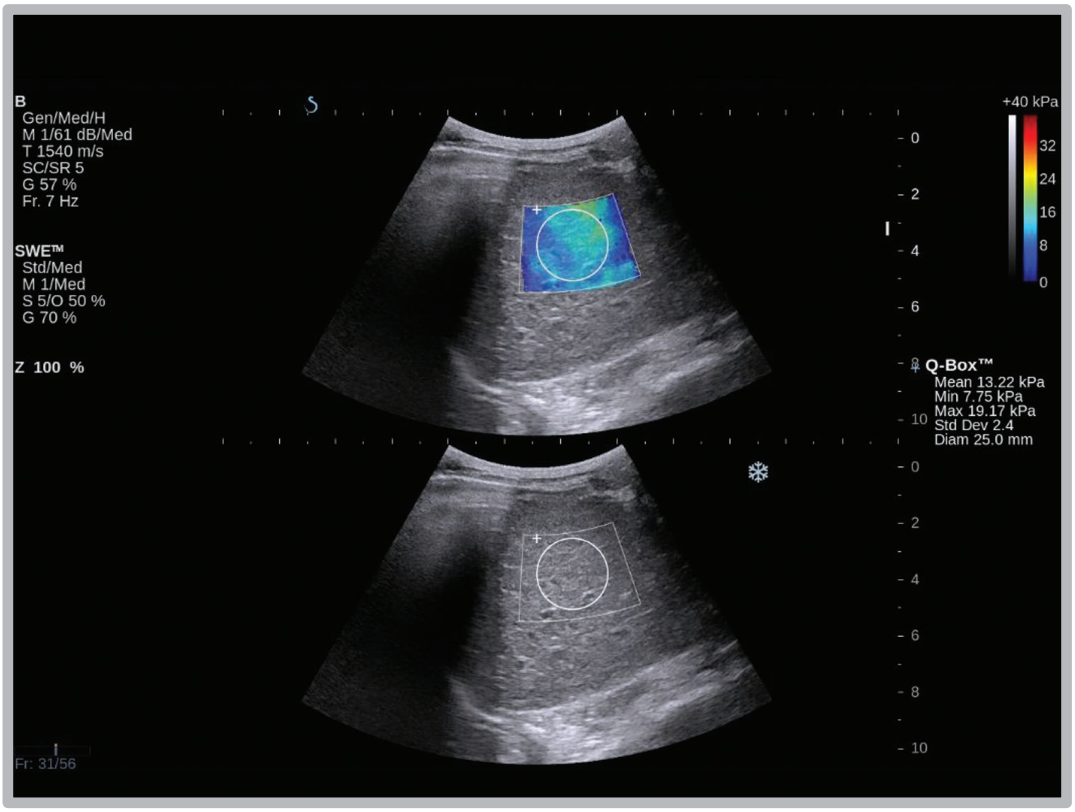

Figure 1. Liver SWE™ imaging in a 40 year-old male HBV carrier patient with cirrhosis.

This non-smoking, non-alcoholic patient with diabetes was a known HBV carrier, with positive Hepatitis B e antigen (HBeAg). Liver ultrasound showed a moderate coarsening of the liver echotexture, with presence of regenerative nodules. The liver stiffness was measured at 13.2 kPa (2.1 m/s), corresponding to a METAVIR F4 score, which was confirmed by liver biopsy.

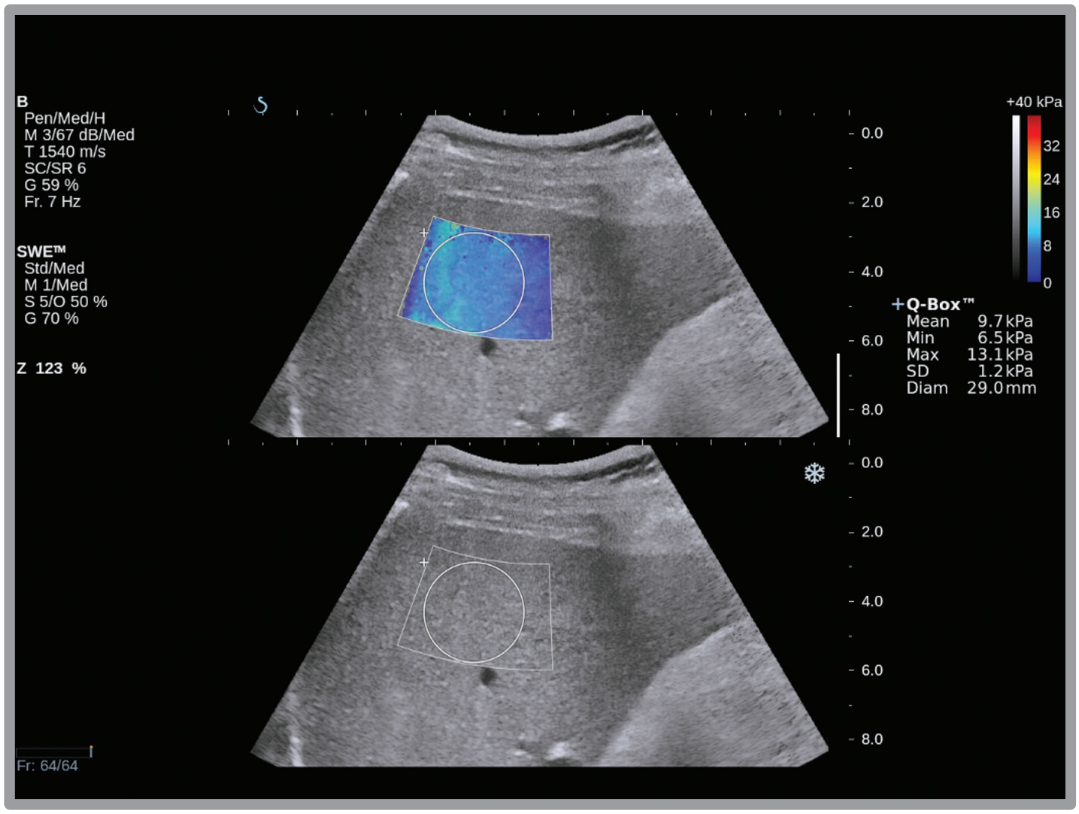

Figure 2. SWE™ assessment of severe liver fibrosis.

This 55 year-old male HBV carrier was an ex-smoker, non-drinker, and presented with colonic polyp. His liver function was impaired, with fluctuating ALT levels up to 91 IU/l. Gray scale ultrasound of the liver showed only mild coarsening of the echotexture. SWE of the liver was performed and liver stiffness was measured at 9.7 kPa (1.8 m/s), which was graded as F≥3. Biopsy proved a METAVIR score F3.

Figure 3. Moderate liver fibrosis assessed by both liver and spleen stiffness.

This 63 year-old male HBV carrier ceased smoking and alcohol consumption since 2000. He presented with reflux esophagitis. On ultrasound examination, the liver showed a normal echotexture, and a spleen of normal size (length: 8.2 cm) with homogenous echotexture. SWE analysis of the liver parenchyma and spleen were performed. Liver elasticity (3A) was measured at 7.3 kPa (1.6 m/s) which corresponded to F≥2, while spleen elasticity (3B) was measured at 19.7 kPa (2.6 m/s) which was approaching the F≥2 splenic cut-off value found to be 19.8 kPa (2.6 m/s) in our experience. Liver biopsy proved a METAVIR F2 score, thus SWE was able to correctly assess liver fibrosis in this case.

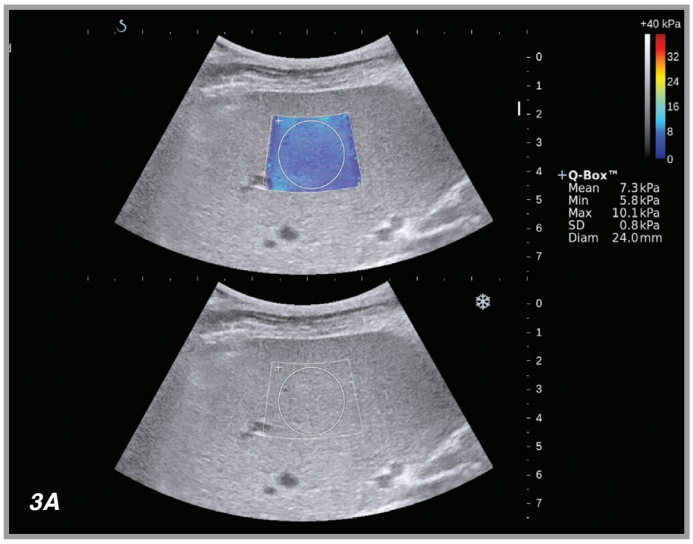

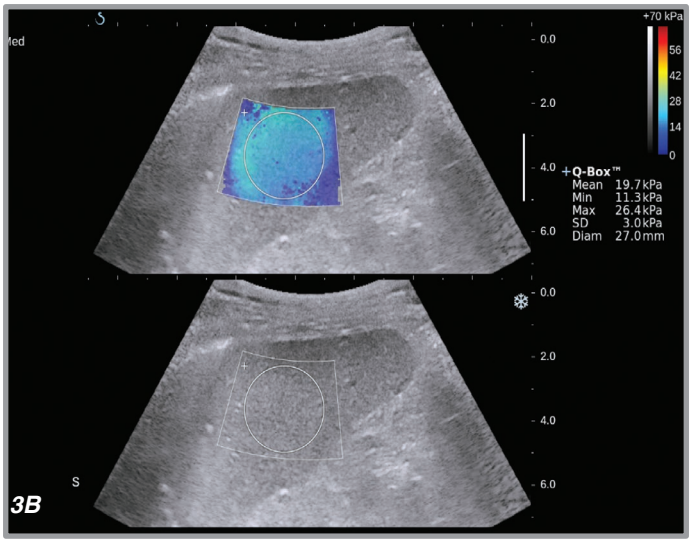

Spleen stiffness measurements

In addition to liver stiffness measurements, preliminary work has been performed on the diagnostic value of spleen stiffness assessment to aid in staging liver fibrosis[9-10]. In our experience with HBV patients, we see a potential application of spleen stiffness SWE™ measurement, especially in the context of severe liver fibrosis and cirrhosis.

As liver fibrosis progresses, splenic architectural changes take place, probably due to hemodynamic alterations, causing splenic stiffness to increase[11-12]. This change in splenic elasticity can be detected and measured by SWE. Although it is more obvious in cases of liver cirrhosis, splenic stiffness can be used in combination with hepatic stiffness to help assess fibrotic stages METAVIR F2 to F4. Our results proved that the optimal cut-off point of spleen stiffness to predict cirrhosis in HBV patients was 21.9 kPa (2.7 m/s). The case presented in Figure 3 demonstrates the additional value of using SWE on the spleen to reinforce liver fibrosis staging and to increase diagnostic accuracy.

As liver fibrosis advances, we observed that the stiffness increase in the liver and the spleen do not follow the same progression curves. We found that the diagnostic use of SWE splenic stiffness for liver fibrosis staging was less accurate than that of SWE liver stiffness. Therefore, we have concluded considering SWE splenic stiffness as an ancillary parameter, which could support the diagnosis of severe fibrosis and cirrhosis in suspicious cases.
Splenic SWE measurements can also be useful when the severity of liver disease does not allow a direct measurement of liver stiffness, as shown in Figure 4.

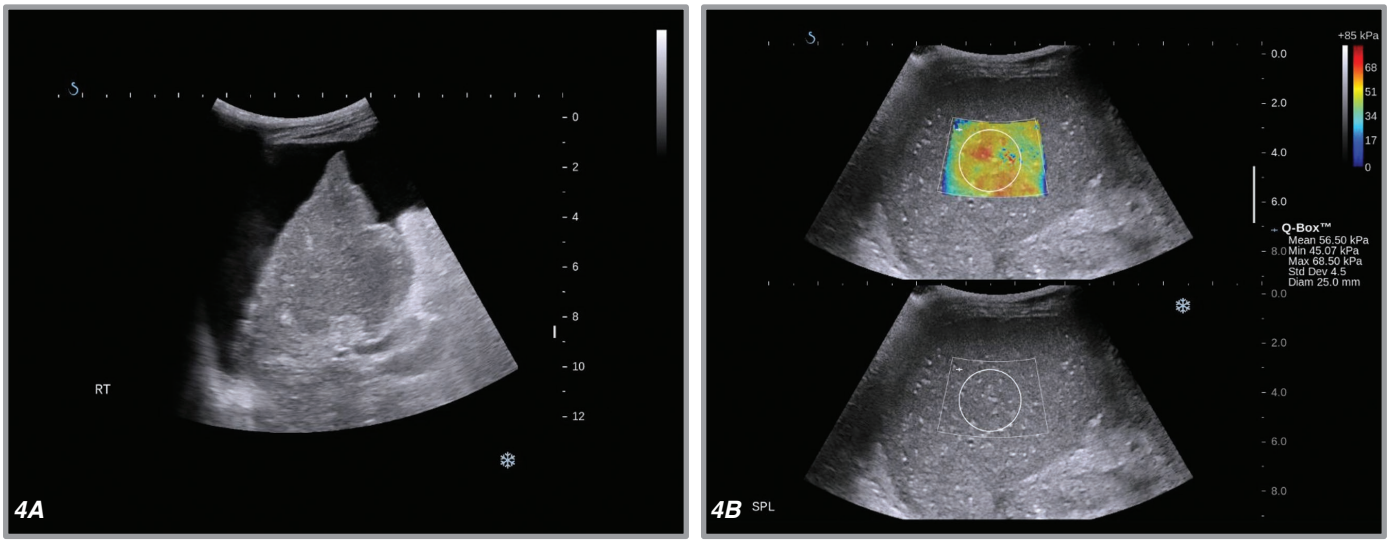

Figure 4. Patient with severe cirrhosis and splenomegaly.
This 82 year-old male patient with HBV biopsy-proven cirrhosis presented with portal hypertension and ascites. As seen in Figure 4A, ultrasound showed a shrunken and cirrhotic liver. The abdominal fluid collection appears clearly on this image. Ascites is not a limitation for the use of SWE in liver stiffness assessment, but a satisfactory liver SWE map could not be obtained in this particular case due to the small size of the liver and the patient's inability to breath-hold for a sufficient time. In this patient, we could diagnose the recanalization of the umbilical vein and splenomegaly (measured length: 16.7 cm) with splenic varices (not shown). The large size of the spleen permitted measurement of splenic stiffness, which proved to be very stiff (56.5 kPa) on Figure 4B.

Conclusion

In conclusion, SWE in the liver provides an accurate correlation between liver elasticity and liver fibrosis staging, and SWE in the spleen may serve as an ancillary parameter in advanced fibrosis. Real time SWE is found to be easy to perform with reproducible, quantitative measurements. It has been integrated into a conventional ultrasound machine, Aixplorer®, and can be performed in the same setting of morphological evaluation of liver cirrhosis and associated complications. Together with hematological and biochemical examination, physicians are provided with a more comprehensive assessment of the fibrotic status of the liver and the spleen in chronic Hepatitis B patients. Early and correct detection of METAVIR stage F2 liver fibrosis is very important, as antiviral and/or anti-fibrotic treatment can be started in a timely manner, thus preventing the progression of fibrosis. SWE is also valuable for longitudinal investigations and for the monitoring of treatment response, particularly for patients with contraindications to liver biopsy.

The advantages of real time scanning, superb resolution, repeatability, reproducibility, quantification and a high acquisition success rate make SWE a promising new technique in ultrasound elastography.

References

1. Noninvasive assessment of liver fibrosis and portal hypertension with transient elastography. Rockey DC. Gastroenterology. 2008 Jan;134(1):8-14.
2. Quantitative viscoelasticity mapping of human liver using supersonic shear imaging: preliminary in vivo feasibility study. Muller M, Gennisson JL, Deffieux T, Tanter M, Fink M. Ultrasound Med Biol. 2009 Feb;35(2):219-29.
3. Noninvasive in vivo liver fibrosis evaluation using supersonic shear imaging: a clinical study on 113 hepatitis C virus patients. Bavu E, Gennisson JL, Couade M, Bercoff J, Mallet V, Fink M, Badel A, Vallet-Pichard A, Nalpas B, Tanter M, Pol S. Ultrasound Med Biol. 2011 Sep;37(9):1361-73
4. Accuracy of real-time shear wave elastography for assessing liver fibrosis in chronic hepatitis C: a pilot study. Ferraioli G, Tinelli C, Dal Bello B, Zicchetti M, Filice G, Filice C; Liver Fibrosis Study Group. Hepatology. 2012 Dec;56(6):2125-33.
5. Liver fibrosis evaluation using real-time shear wave elastography: Applicability and diagnostic performance using methods without a gold standard. Poynard T, Munteanu M, Luckina E, Perazzo H, Ngo Y, Royer L, Fedchuk L, Sattonnet F, Pais R, Lebray P, Rudler M, Thabut D, Ratziu V. J Hepatol. 2013 Jan 12. doi:pii: S0168-8278(13)00008-1. 10.1016/j.jhep.2012.12.021.
6. Reproducibility of real-time shear wave elastography in the evaluation of liver elasticity. Ferraioli G, Tinelli C, Zicchetti M, Above E, Poma G, Di Gregorio M, Filice C. Eur J Radiol. 2012 Nov;81(11):3102-6.
7. EASL clinical practice guidelines: Management of chronic hepatitis B virus infection. European Association For The Study Of The Liver. J Hepatol. 2012 Jul;57(1):167-85. Erratum in J Hepatol. 2013 Jan;58(1):201.
8. Diagnosis, Management, and Treatment of hepatitis C: an update. Ghany MG, Strader DB, Thomas DL, Seeff LB. Hepatology 2009; 49: 1335–1374.
9. Measurement of spleen stiffness to evaluate portal hypertension and the presence of esophageal varices in patients with HCV-related cirrhosis. Colecchia A, Montrone L, Scaioli E, Bacchi-Reggiani ML, Colli A, Casazza G, Schiumerini R, Turco L, Di Biase AR, Mazzella G, Marzi L, Arena U, Pinzani M, Festi D. Gastroenterology. 2012 Sep;143(3):646-54.
10. Elastography, spleen size, and platelet count identify portal hypertension in patients with compensated cirrhosis. Berzigotti A, Seijo S, Arena U, Abraldes JG, Vizzutti F, García-Pagán JC, Pinzani M, Bosch J. Gastroenterology. 2013 Jan;144(1):102-111.
11. Liver elastography for the diagnosis of portal hypertension in patients with liver cirrhosis. Şirli R, Sporea I, Bota S, Raţiu I. Med Ultrason. 2012 Sep;14(3):225-30.
12. The accuracy of noninvasive methods in predicting the development of hepatocellular carcinoma and hepatic decompensation in patients with chronic hepatitis B. Chon YE, Jung ES, Park JY, Kim do Y, Ahn SH, Han KH, Chon CY, Jung KS, Kim SU. J Clin Gastroenterol. 2012 Jul;46(6):518-25.

AIXPLORER MultiWave

SUPERSONIC imagine
The Theragnostic Company™

SuperSonic Imagine France
Les Jardins de la Duranne Bât. E & F
510, rue René Descartes
13857 Aix-en-Provence Cedex
France
✆ +33 (0)4 88 19 68 55
🖷 +33 (0)4 42 52 59 21
✉ contactsFR@supersonicimagine.com

SuperSonic Imagine, Inc USA
11714 North Creek Parkway N, Suite 150
Bothell, WA 98011
USA
✆ +1 (425) 686 6380
🖷 +1 (425) 686 6387
✉ contactsUSA@supersonicimagine.com

SuperSonic Imagine GmbH Germany
Zeppelinstr. 71-73
81669 München
Germany
✆ +49 89 36036 844
🖷 +49 89 36036 700
✉ contactsDE@supersonicimagine.com

SuperSonic Imagine Asian Distribution Network
Les Jardins de la Duranne Bât. E & F
510, rue René Descartes
13857 Aix-en-Provence,
France
✆ +33 (0)4 88 19 68 55
🖷 +33 (0)4 42 52 59 21
✉ contactsASIA@supersonicimagine.com

SuperSonic Imagine China
Room 2304, Block D, Ocean
International,Dong, SiHuan ZhongLu
Chaoyang District, Beijing (100025)
China
✆ +86-10- 85861023/ 2951/ 2917
🖷 +86-10-8586 2389

www.supersonicimagine.com

SSID02973 / 340v1